



Basic management of epistaxis

May 31st 2017

Ulrika Clarhed

Resident in ENT

Department of Otorhinolaryngology, Head & Neck Surgery

Sahlgrenska University Hospital, Gothenburg, Sweden

Schedule for today

Part I

- ▶ Anatomy, definitions
- ▶ A Swedish article – Basic management of epistaxis
 - ▶ Chemical/electrical cautery
 - ▶ Anterior nasal packing
 - ▶ RapidRhino®
 - ▶ Foley catheter posterior nasal packing
- ▶ What and when?

Part II

- ▶ When conservative treatment fails – what options do we have?

Cecilia Ahlström-Emanuelsson

MD, PhD, senior consultant

Department of Otorhinolaryngology, Head & Neck Surgery, Skåne

University Hospital, Lund, Sweden



Definitions

- Anterior epistaxis
- Posterior epistaxis

Definitions

- Anterior epistaxis
→ bleeding from the area anterior to the middle turbinate¹
- Posterior epistaxis

¹Shargorodsky, J et al. *Outcomes Analysis in Epistaxis Management: Development of a Therapeutic Algorithm*. Otolaryngology-Head and Neck Surgery 2013;149:390-398.

Definitions

- Anterior epistaxis

 - bleeding from the area anterior to the middle turbinate¹

- Posterior epistaxis

 - source of bleeding beyond visualization with a nasal speculum and headlight²

¹Shargorodsky, J et al. *Outcomes Analysis in Epistaxis Management: Development of a Therapeutic Algorithm*. Otolaryngology-Head and Neck Surgery 2013;149:390-398.

²Rudmik, L & Smith TL. *Management of intractable spontaneous epistaxis*. American Journal of Rhinology & Allergy 2012;26:55-60.

- Bleeding from the anterior part is most common (90-95 %)¹
- Preventive measures include keeping the nasal mucosa moist and intact. This can be achieved by the patient by using oil and/or saltwater spray. One study has shown that oil is superior to saltwater spray.²
- And perhaps more importantly – do our patients follow our recommendations?

¹Viehweg TL, Roberson JB, Hudson JW. *Epistaxis: Diagnosis and Treatment*. J Oral Maxillofac Surg. 2006;64:511-8.

²Johnsen J, Bratt BM, Michel-Barron O, et al. *Pure sesame oil vs isotonic sodium chloride solution as treatment for dry nasal mucosa*. Arch Otolaryngol Head Neck Surg. 2001;127:1353-6.

Self-care recommendations

- ▶ Sit up! Avoid lying down if possible as this will increase the blood flow to the head and nose. Also, when in upright position it is easier to avoid swallowing blood.
- ▶ Remove coagulated blood by blowing your nose. Apply cotton swabs with decongestant spray (oxymetazolin/xylometazolin) or oil with pressure for 20 minutes
- ▶ Put an ice cube in your mouth
- ▶ Seek medical care if continued bleeding.¹

¹Friis-Liby J, Groth A. redaktörer ÖNH-handboken. Lund: Studentlitteratur;2010.p.151.

Basic management of epistaxis

- ▶ PubMed search:

- ▶ epistaxis management
- ▶ anterior/posterior epistaxis
- ▶ duration of nasal packs
- ▶ RapidRhino epistaxis
- ▶ Foley catheter epistaxis

- ▶ Limited evidence based on randomized studies when it comes to basic management of epistaxis¹

¹Läkartidningen. 2016;113:DR7F

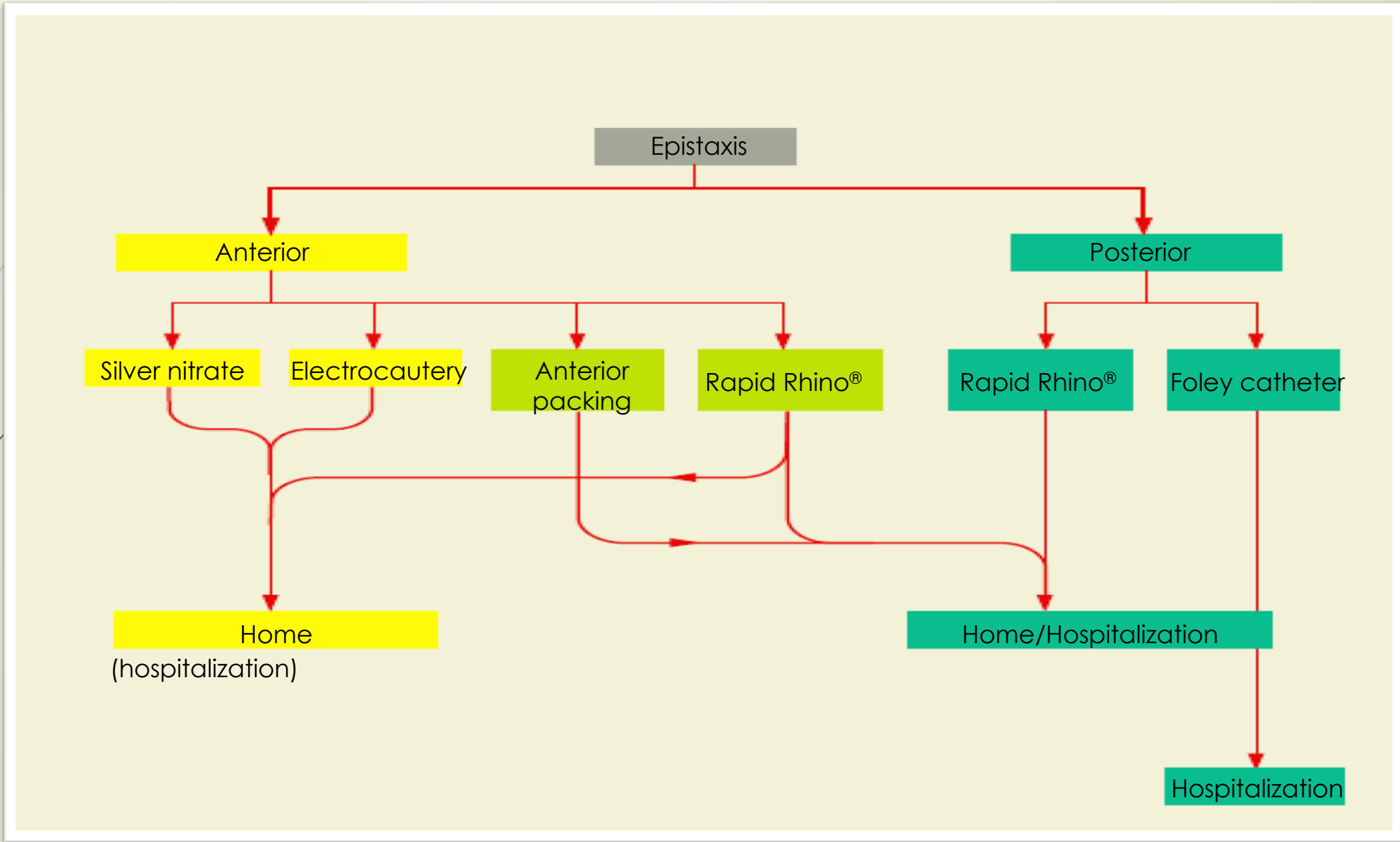
A practical guide on basic management of epistaxis

- ▶ ABC om Praktisk handläggning av näsblödning¹
- ▶ Johan Hellgren, Ulrika Svensson
- ▶ Cecilia Ahlström-Emanuelsson, Morgan Andersson, Mats Holmström, Thomas Eriksson, Henrik Bergqvist, Anders Ebenfelt, Gunnhildur Gudnadottir, Kenneth Holmberg, Erik Odelberg, Erik Odhagen, Björn Petruson, Åsa Robinson.

¹Läkartidningen. 2016;113:DR7F



And these are our results...



Identifying the source of the bleeding

- ▶ Proper instruments and precautions
- ▶ Assistance
- ▶ Where does the bleeding derive from? Ask the patient from which side it started!
- ▶ Careful inspection
- ▶ Oropharynx

Silver nitrate sticks

1. Topical anesthetic 5-10 minutes
2. Remove coagulated blood
3. Apply silver nitrate stick to bleeding source 5-10 seconds
4. Apply cotton swab prepared with oil which the patient removes himself/herself after a few hours



Electrocautery

1. Topical anesthetic 5-10 minutes
2. Remove coagulated blood
3. The device should be set to the lowest effect, place the tips over the bloodvessel.
4. Apply cotton swab prepared with oil which the patient removes himself/herself after a few hours

Discussion chemical/electrical cautery

- ▶ Electrical cautery is more painful compared to chemical cautery
- ▶ Electrical cautery is also more potent compared to chemical cautery
- ▶ Septal perforation after septal cautery is rare but is more often seen in patients treated multiple times and on both sides at the same time. For this reason, only one side should be treated at a time with a week or more in between.

Anterior nasal packing

1. Remove coagulated blood
2. Topical anesthetic 5-10 minutes
3. Apply anterior packing (gauze prepared with an antibiotic ointment, Terracortril with polymyxin B)



Rapid Rhino®

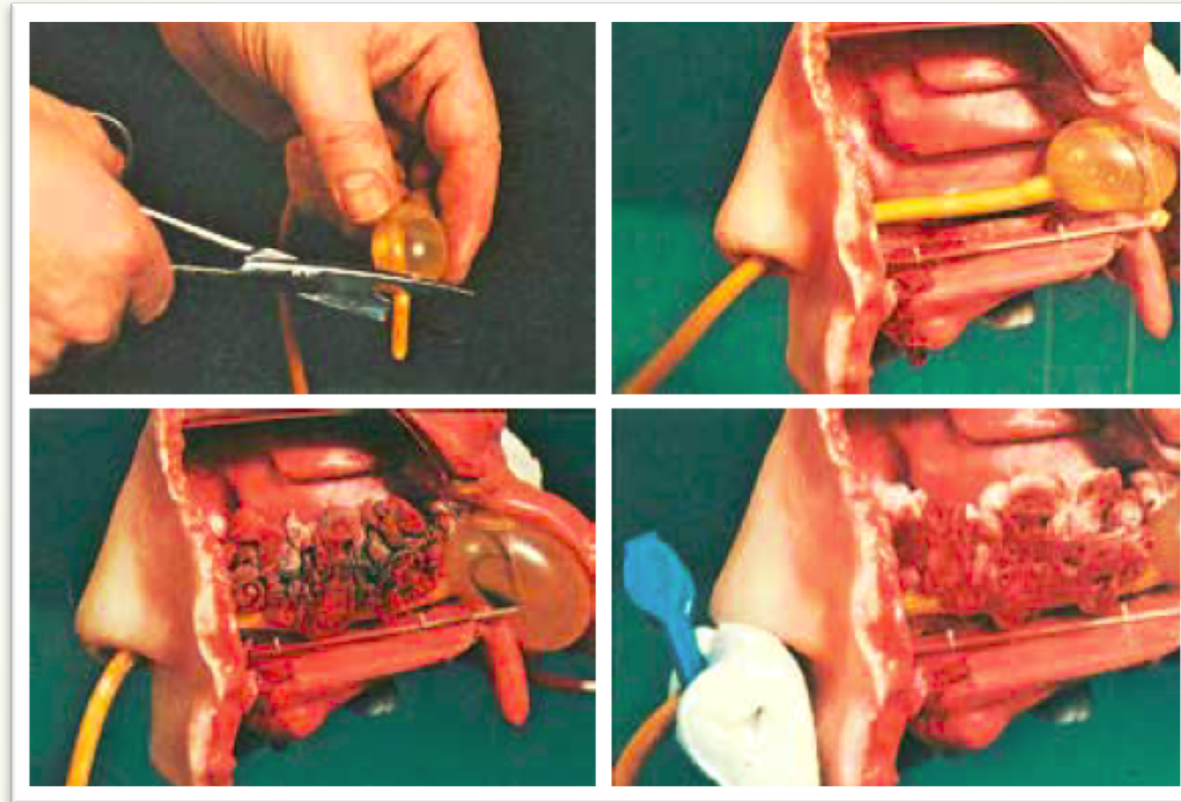
1. Remove coagulated blood
2. Topical anesthetic 5-10 minutes
3. Soak in sterile water for 30 seconds to pre-lubricate
4. Insert the RapidRhino® in meatus media/inferior parallel to the nasal floor.
5. Using a syringe, slowly begin filling the balloon with air (start with 3-5 ml). Compress the safety balloon for direct tactile feedback of the balloon pressure inside the nasal cavity. Keep eye contact with the patient!
6. Many patients are able to empty and remove the RapidRhino® themselves.

Discussion RapidRhino®

- ▶ Applying RapidRhino® to patients with septal deviation may be impossible. These patients should instead be treated with Foley catheter posterior nasal packing.
- ▶ When a health center lacks means of chemical or electrical cautery, the RapidRhino® may be used to temporarily stop the bleeding whilst transporting the patient to the emergency room.

Foley catheter posterior nasal packing

1. Cut the tip of the catheter to avoid irritation in the nasopharynx. The Foley catheter is unmarked which may make it difficult to inflate at precisely the right location. Therefore, make a mark on the catheter 8 cm from the proximal end of the inflated balloon.
2. Remove coagulated blood
3. Pre-lubricate the catheter with topical anesthetic gel and apply parallel to the nasal floor.
4. When the catheter is in place, inflate the balloon with sterile water, 7-10 ml to start with.
5. Pull the balloon firmly in place in the nasopharynx.
6. Apply nasal packing with gauze prepared in Terracortril with polymyxin B or decongestant nasal spray.
7. The catheter is secured using a clip and a dressing to protect the skin



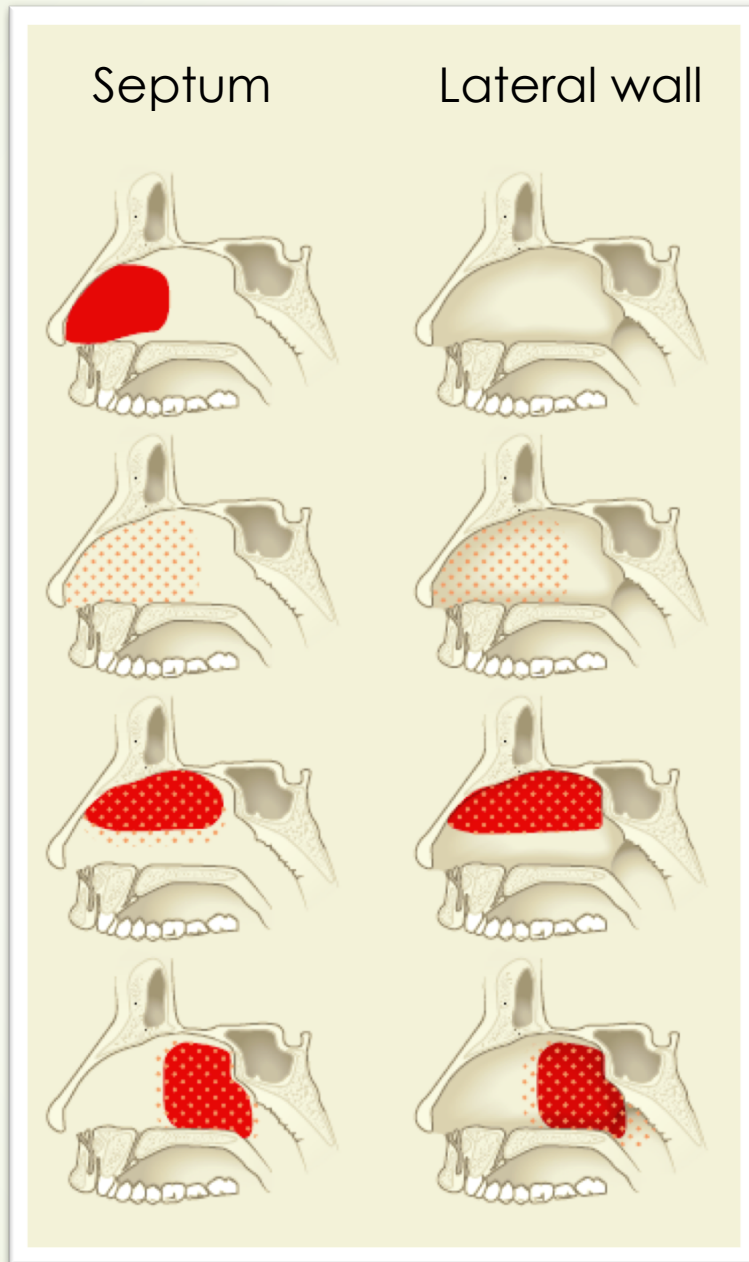
Läkartidningen. 2016;113:DR7F



Discussion Foley catheter

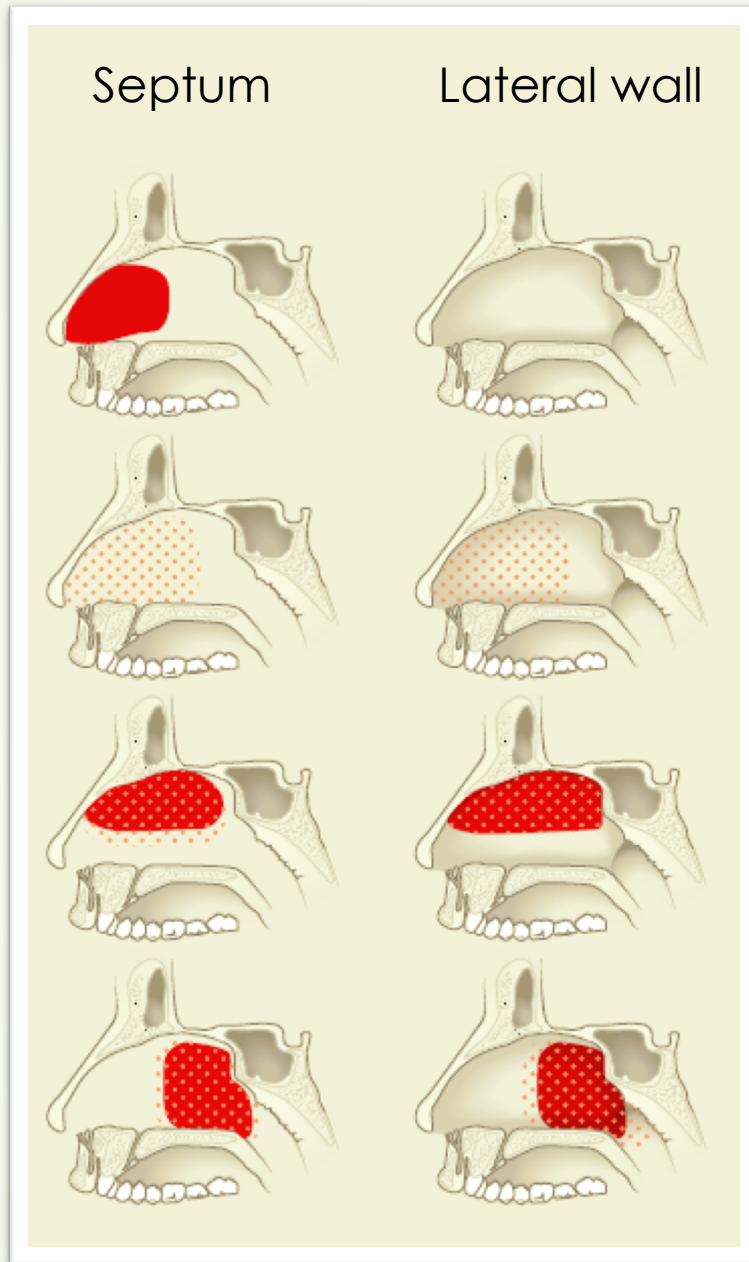
- ▶ There are catheters specifically designed for the nose. The Foley catheter is designed for use in the urinary tract. However, it is well-known and can be found in emergency rooms and health centers, hence its advantage.
- ▶ Patients receiving this type of packing should be admitted to an ENT-clinic and remain in hospital
- ▶ Daily assessment of nasal skin as to avoid damage to the skin caused by pressure
- ▶ Removal of the pressure in the balloon after 24 hours at most in order to avoid damage to the nasopharynx
- ▶ Systemic anesthesia (paracetamol, NSAID, morphine in some cases)
- ▶ Patients with a nasal tamponade and sedation are at risk of developing hypoxia and should therefore be monitored in hospital

Discussion

- ▶ When applying a nasal tamponade which exerts pressure on the nasal mucosa one must always continuously evaluate when the tamponade can be removed
- ▶ Generally:
 - ▶ a tamponade in form of a balloon which expands in the nose should if possible be removed within 24 h
 - ▶ soft tamponades (gauze) prepared in antibiotic ointment can be applied for longer periods
- ▶ Each case must be assessed individually with consideration taken to the extent of epistaxis, patient age, general health and medication





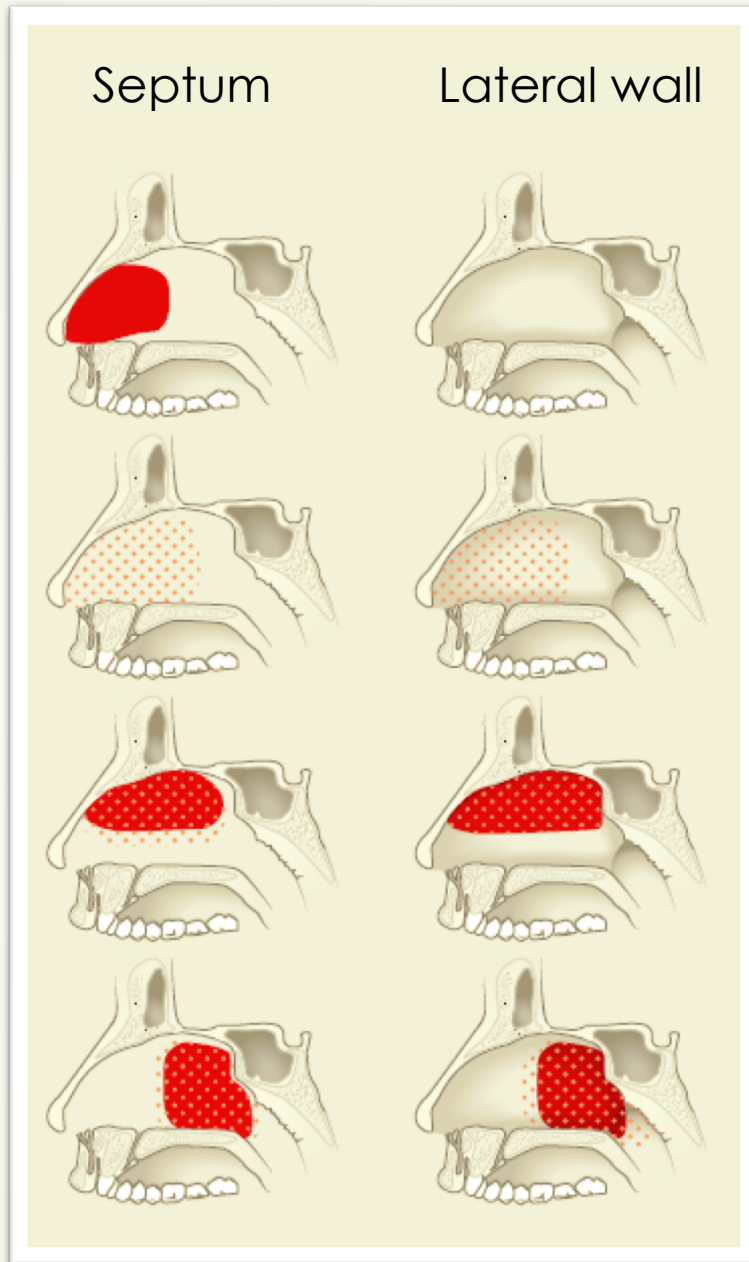
-  Diffuse bleeding
-  Distinct bleeding



→ Chemical/electrical cautery





-  Diffuse bleeding
-  Distinct bleeding

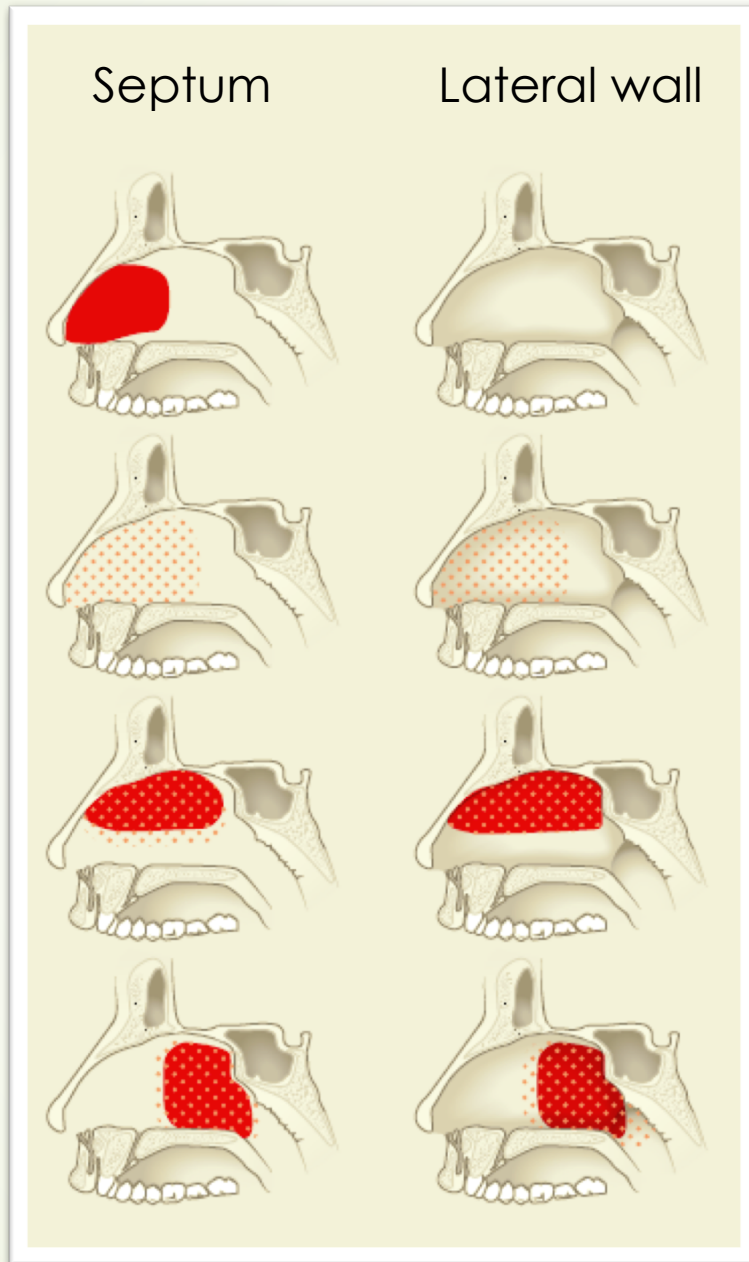


→ Chemical/electrical cautery

→ Anterior packing with gauze



 Diffuse bleeding
 Distinct bleeding





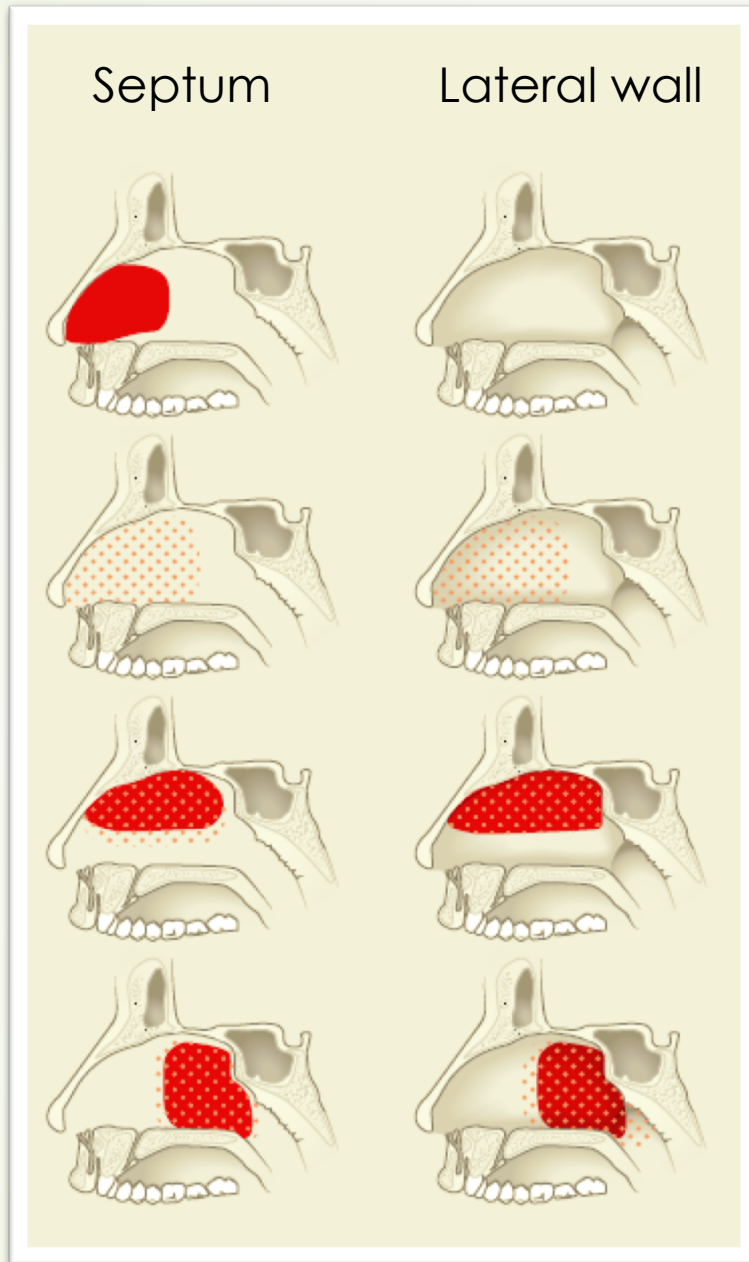
→ Chemical/electrical cautery

→ Anterior packing with gauze

→ Anterior packing with gauze applied to the nasal roof and RapidRhino® OR Foley catheter



	Diffuse bleeding
	Distinct bleeding





→ Chemical/electrical cautery

→ Anterior packing with gauze

→ Anterior packing with gauze applied to the nasal roof and RapidRhino® OR Foley catheter



→ Foley catheter OR RapidRhino® with dual balloons


	Diffuse bleeding
	Distinct bleeding






➤ Use of RapidRhino®?



- 
- 
- Use of RapidRhino®?
 - Topical anesthesia with cotton swabs – how long?

- 
- Use of RapidRhino®?
 - Topical anesthesia with cotton swabs – how long?
 - Topical anesthesia, both cotton swab and injection, before electrical cautery?

- 
- 
- Use of RapidRhino®?
 - Topical anesthesia with cotton swabs – how long?
 - Topical anesthesia, both cotton swab and injection, before electrical cautery?
 - Chemical/electrical cautery – how much time should pass before treating the contralateral side?

- 
- Use of RapidRhino®?
 - Topical anesthesia with cotton swabs – how long?
 - Topical anesthesia, both cotton swab and injection, before electrical cautery?
 - Chemical/electrical cautery – how much time should pass before treating the contralateral side?
 - Foley catheter – sterile water or sodium chloride?



The end of part I